Method to quantify the decentration of the multifocal intraocular lenses in relation to the visual axis in eyes following phacoemulsification

Fernando Polit, MD[1,2]
Andres Polit, MD[3]
Joaquin Polit , MD[4]

[1] Hospital Clínica Kennedy.
[2] Clínica Internacional de la Visión de Ecuador. Guayaquil, Ecuador.
[3] Fellow of Cornea, Refractive and Anterior Segment Surgery, Clínica Carriazo.
[4] Escuela Superior de Oftalmología, Instituto Barraquer de América, Bogotá, Colombia.

Corresponding author: Dr. Fernando Polit
Samborondón Km 1 1/2 vía La Puntilla Samborondón
092301, Guayaquil, Equador.
Email: andresfpolith@gmail.com

Funding: None

Proprietary/financial interest: None

Date of submission: 08/12/2018

Date of approval: 19/12/2018

Introduction

Since position and centration have shown to affect the effectiveness of multifocal intraocular lenses (MFIOLs), some authors have proposed using the "coaxially sighted IOL light reflex" (CSILR) as a landmark to allow consistent centration of MFIOLs.[1] Postoperatively, assessing the location of the intraocular lens concerning the visual axis is also important. Centration of the MFIOLs can be identified postoperatively by slit lamp biomicroscopy, but it is still a qualitative method.[2] The Nidek OPD Scan III is an autorefractor, keratometer, pupillometer, corneal topographer, and wavefront aberrometer. Among some other functions, the instrument obtains retro illumination images, which allows the observation of the diffractive rings of the multifocal intraocular lenses implanted following phacoemulsification.[3]

Figure 1. Distance from the center of the pupil in photopic conditions to the visual axis.

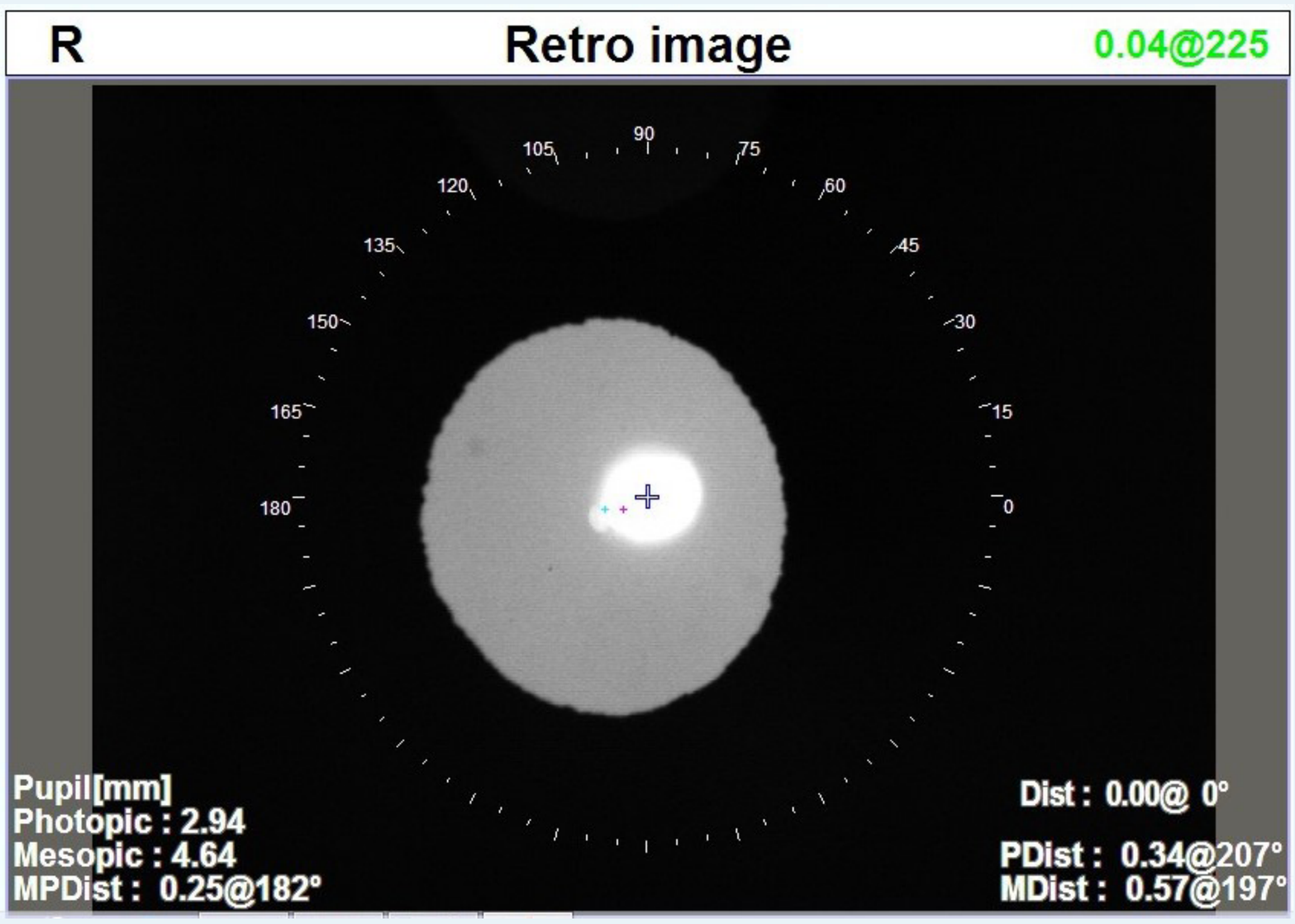

Figure 1. The white cross with blue borders (+) indicates the location of the visual axis, which is described in the legend on the bottom right of the picture (Dist: 0.00 to 0°). The distance from the center of the pupil in photopic conditions to the visual axis (PDist: 0.34 to 207° is mentioned below.) This means that the visual axis is 0.34 millimeters and 27° from the center of the photopic pupil. Below this legend is described the same, but with the pupil in mesopic conditions (PDist: 0.57 to 197°).

Methods

The Nidek OPD Scan III was used. The instrument obtains retro-illumination images, which allows the observation of the diffractive rings of the multifocal intraocular lenses implanted following phacoemulsification.

The retro-illumination image describes the location of the visual axis (white cross with blue borders +), the center of the photopic (pink cross) and mesopic (turquoise cross) pupil, quantifies the distance between the center of the pupil and the visual axis, and places the visual axis in degrees (*Figure 1*).

Figure 2a shows the postoperative of an intraocular lens Panoptix®. The lens seems to be centered with the visual axis, but it needs to be corroborated. For this purpose, an acetate grid that includes a cross and a center circle (*Figure 2b*) can be used, which is placed on the screen of the monitor that shows the image by backlighting.

Figure 2. The intraocular lens seems to be well centered with the visual axis.

Figure 2a. *Apparently, the intraocular lens seems to be well centered with the visual axis.*
Figure 2b. *Acetate grid.*

Results

It is attempted to match the rings of the lens with that of the acetate grid. Once the best possible equidistance between the lens and grid rings has been achieved, the cursor is relocated to the center of the acetate cross. The instrument allows the cursor to move (white cross with blue edges +) and in this way, it can be placed in the center of the first diffractive ring of the multifocal intraocular lens. By moving the cross, the instrument gives us the reading in millimeters and degrees of its new location relative to the starting point, this is, the visual axis (*Figure 3*).

Figure 3. The cursor has been relocated in the center.

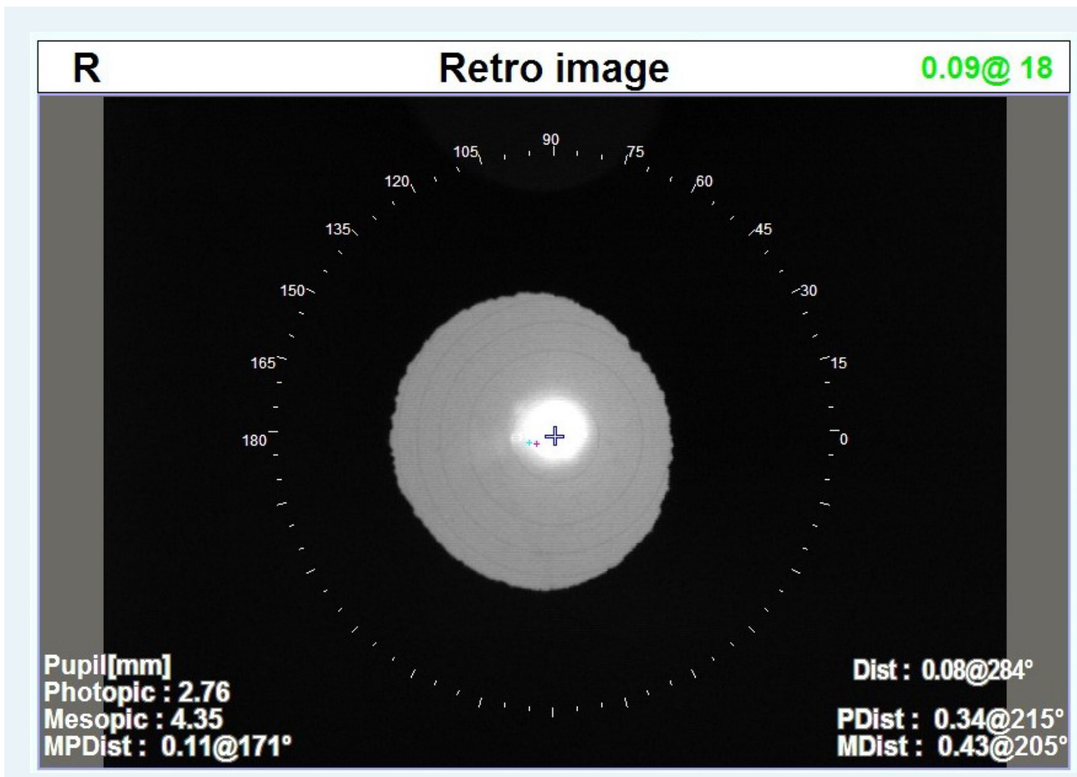

Figure 3. *The cursor (white cross with blue edges +) has been relocated in the center of the first diffractive ring of the Panoptix intraocular lens, which is 0.08 mm at 284° from the visual axis.*

Figure 3. The cross of the blue circle has coincided with the white cross representing the center of the intraocular lens.

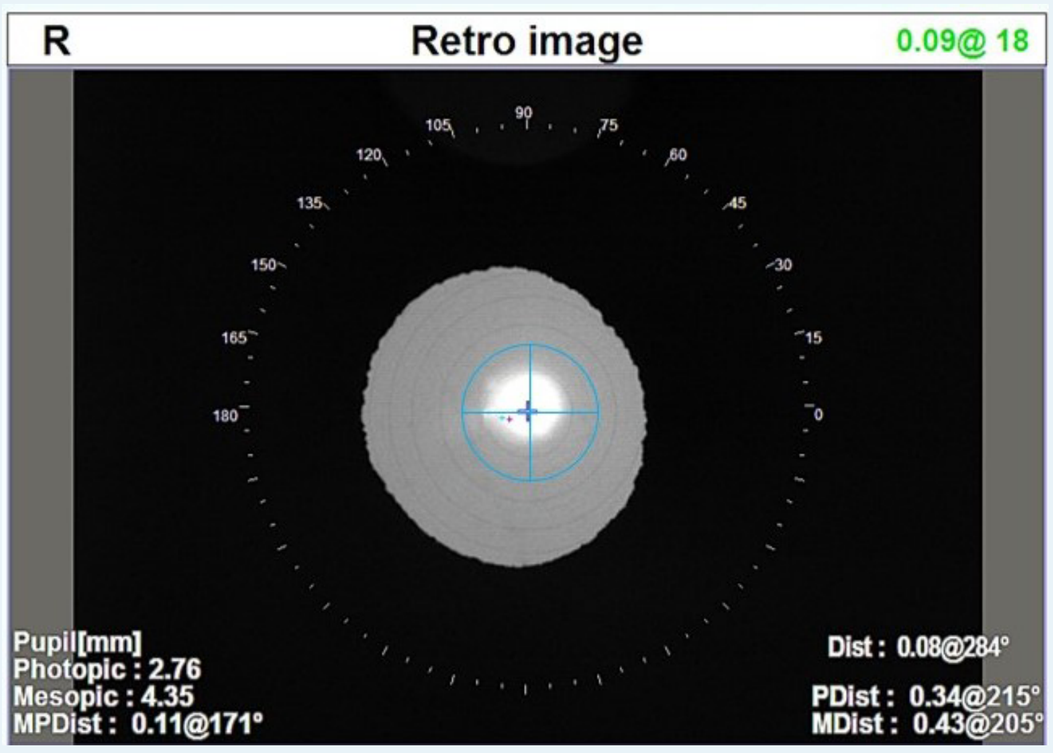

Figure 4. *The cross of the blue circle has coincided with the white cross representing the center of the intraocular lens, this is, the lens was slightly off center and nasal relative to the visual axis.*

The image is captured and analyzed in a PowerPoint file. With the help of a reticulated circle (chosen to be light blue), the cross coincides with the center of the multifocal lens (*Figure 4*).

Discussion

This method can be useful to be able to have a reference of a real value of decentration of the lenses and thus have a surgical plan and try to center the lenses. We are also creating a technique to properly center the lenses, in addition to performing an analysis of the results regarding postoperative visual quality about the lens's decentration and thus see how this affects.

Conclusion

This new method is an effective method to quantify decentration of the multifocal intraocular lenses with the visual axis in eyes following phacoemulsification.

References

1. Hayashi K, Hayashi H, Nakao F, Hayashi F. Correlation between pupillary size and intraocular lens decentration and visual acuity of a zonal progressive multifocal lens and a monofocal lens. *Ophthalmology.* 2001;108:2011-7.
2. Samir A. Melki, Mona Harissi-Dagher. Coaxially sighted intraocular lens light reflex for centration of the multifocal single piece intraocular lens. *Can J Ophthalmol.* 2011; 46(4):319-21.
3. Gualdi Luca, Cappello Veronica, Giordano Cristina. The Use of NIDEK OPD Scan II Wavefront Aberrometry in Toric Intraocular Lens Implantation. *J Refract Surg.*2009;25:S110-S115.